

Agita Jukna, Ilze Strumfa, Andrejs Vanags, Janis Gardovskis

Rīga Stradiņš University, Rīga, Latvia

# EXPRESSION OF p53 PROTEIN IN LUNG CANCER



RĪGAS STRADIŅA  
UNIVERSITĀTE

VITA BREVIS ARS LONGA

# Background

- Lung cancer is clinically, morphologically and molecularly heterogeneous disease. The main prognostic factor is the stage of the tumour depending on TNM classification (Travis *et al.*, 2015).
- Valuable data are provided by the tumour molecular characteristics, especially the alteration of apoptosis, expression of the transcription factor and tumour suppressor p53 protein that has a potential of becoming a target for novel treatment options (Uramoto *et al.*, 2006).

## Aim

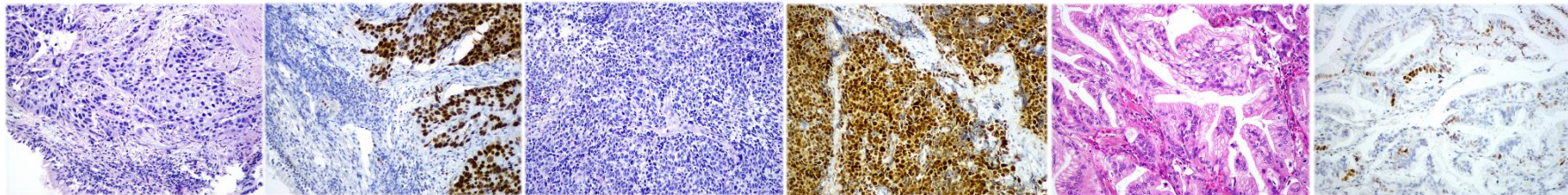
- To evaluate p53 protein expression in primary lung adenocarcinoma, squamous cell carcinoma and small cell carcinoma.

# Materials and methods

- Retrospective study included 30 consecutive cases of primary lung adenocarcinoma, squamous cell carcinoma and small cell carcinoma each that were acquired from the lung biopsy and pulmonary resection material.
- p53 protein expression was evaluated by immunohistochemistry and assessed by computer-assisted morphometry in tumour areas with the highest marker expression.
- The p53 was regarded positive if intense nuclear staining was found in 10% or more of the tumour cells.

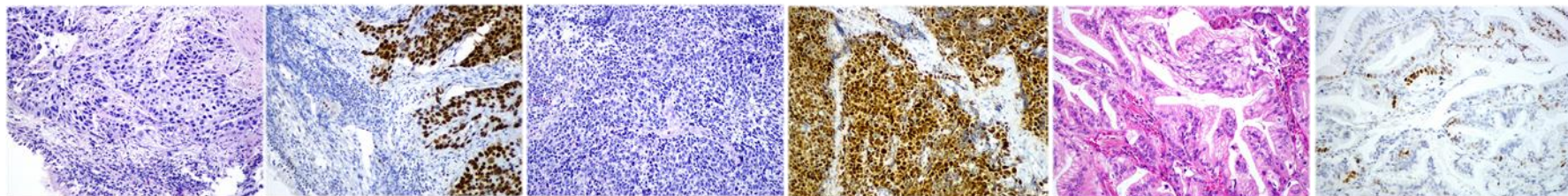
# Results (I) – Mean p53 protein expression in lung carcinomas

Histological type of lung cancer	Mean p53 expression, %	Confidence interval (95%)
<b>Adenocarcinoma</b>	35.5	24.8 – 46.1
<b>Squamous cell carcinoma</b>	46.0	33.0 – 58.9
<b>Small cell carcinoma</b>	40.6	27.6 – 53.6



## Results (II) - Occurrence of p53-positive cases by the histological type of lung cancer (threshold of 10% positive tumour cells)

Histological type of lung cancer	Count, n	Frequency, %	Confidence interval (95%)
<b>Adenocarcinoma</b>	23	76.7	59.1 – 88.2
<b>Squamous cell carcinoma</b>	22	73.3	55.6 – 85.8
<b>Small cell carcinoma</b>	20	66.7	48.8 – 80.8



Thank You!